

PERIODONTAL STRUCTURES

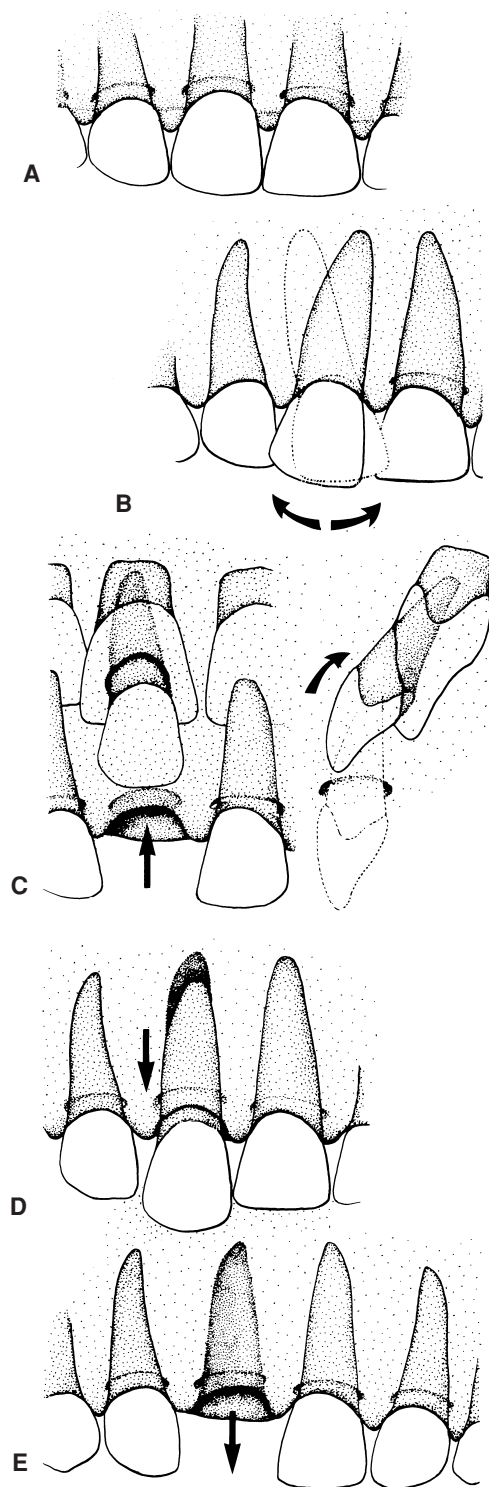


FIGURE 3. The various types of trauma to the periodontal structures: concussion/subluxation (A), lateral luxation (B), intrusion (if primary tooth is intruded note location of developing permanent tooth bud) (C), extrusion (D), and avulsion (E). Refer emergencies B through E to the dental staff as soon as possible. (From Fleisher GR, Ludwig S, Henretig FM, et al. *Textbook of Pediatric Emergency Medicine*. 5th ed. Philadelphia: Lippincott Williams & Wilkins; 2005.)